A Conceptual Review of Vagus Nerve Stimulation: From Neuroanatomy to Clinical Applications

Dr Tania Anand*[1], Dr Subhash Upadhyay*[2], Dr Sakshi*[3], Dr Dinesh yadav*[4]

*[1]PG scholar 1st year, PG Department of Rachana Sharir, Sri Ganganagar college of Ayurvedic science and hospital, Tantia university, Sri Ganganagar

*2HOD & Professor, PG Department of Rachana Sharir Sri Ganganagar College of Ayurvedic science and hospital, Tantia University, Shri Ganganagar, India.

*3Associate Professor, PG Department of Rachana Sharir Sri Ganganagar College of Ayurvedic science and hospital, Tantia University, Shri Ganganagar, India.

*4Assistant Professor, PG Department of Rachana Sharir Sri Ganganagar College of Ayurvedic science and hospital, Tantia University, Shri Ganganagar, India.

Received:Oct 09, 2026 Accepted:Nov 06, 2026 Published:Nov 09, 2026

Abstract

The **vagus nerve** (cranial nerve X) is the longest and most widely distributed cranial nerve. It acts as the main **parasympathetic** link between the brainstem and the organs of the chest and abdomen. The **vagus nerve** arises from four **nuclei** in the brainstem, leaves the skull through the jugular foramen, travels within the carotid sheath, and gives off organ-specific branches in the neck, thorax, and abdomen. It carries **parasympathetic**, branchial **motor**, **visceral sensory**, and somatic **sensory** fibers, allowing two-way communication between the brain and the body.

Vagus nerve stimulation (VNS) is a **neuromodulation** technique that delivers electrical impulses to the vagus nerve to modulate central and autonomic nervous system activity.[1] It is an established therapy for drug-resistant epilepsy and treatment-resistant depression, with growing evidence in post-stroke rehabilitation, obesity, migraine, cluster headache, and inflammatory disorders.[2] This article reviews the anatomical basis, mechanisms, clinical applications, adverse effects.

The FDA has approved another vagus nerve stimulation device for use after a stroke. For people who have trouble using their hand or arm after a stroke, the device helps make new pathways in the brain during exercise. This can help people regain the use of the affected hand or arm.[8]

A solid grasp of the **vagus nerve's** gross and functional anatomy is essential for understanding its physiological roles, the clinical conditions that arise when it is damaged, and its growing importance in neuromodulation therapies.

Keywords: - vagus nerve, sensory, motor, parasympathetic, nuclei, visceral, vagus nerve stimulation, neuromodulation

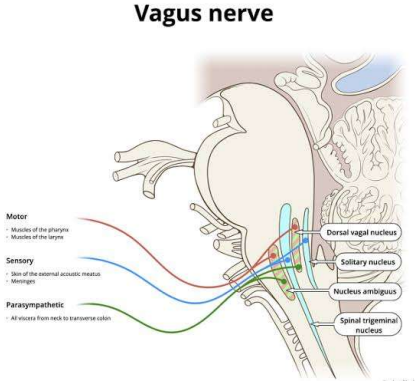

Introduction

The **vagus nerve** is the tenth cranial nerve and the longest cranial nerve in the human body. It contains approximately 80% afferent fibres that carry **sensory** information from the thorax and abdomen to the brainstem, while the remaining efferent fibres regulate **parasympathetic** functions of the heart, lungs, and gastrointestinal tract.[3] It sits at the heart of autonomic regulation,

gut–brain communication, and neuroimmune control, making it a cornerstone of both classical anatomy and modern bioelectronic medicine.

VNS refers to deliberate stimulation of the **vagus nerve**, usually through an implanted pulse generator connected to a lead placed around the left cervical **vagus nerve**.[4] More recently, non-invasive transcutaneous auricular **VNS** (taVNS) has been developed by stimulating the auricular branch of the **vagus nerve** through the skin.[5]

Vagus nerve stimulation involves using a device to send electrical impulses to the **vagus nerve**. The **vagus nerve** is the main nerve of the system that controls digestion, heart rate and other vital functions. When the device fires, it sends electrical impulses to areas of the brain. This changes brain activity to treat certain conditions.[8]

Devices for **vagus nerve stimulation** include one the Food and Drug Administration (FDA) approved that goes into the body, to treat epilepsy and depression. It works by sending impulses to areas of the brain that cause seizures and affect mood.[8]

The FDA has approved another vagus nerve stimulation device for use after a stroke. For people who have trouble using their hand or arm after a stroke, the device helps make new pathways in the brain during exercise. This can help people regain the use of the affected hand or arm.[8]

Surgeons put these devices under the skin in the chest. A wire threaded under the skin connects the device to the left **vagus nerve**. The device sends electrical signals along the left **vagus nerve** to the brainstem to affect the brain.[8]

There's also a **vagus nerve** on the right side of the body. Surgeons don't often use the right **vagus nerve** because it's more likely to affect how the heart works.[8]

Clinically, the **vagus nerve** is encountered in a wide range of settings. In the neck and thorax, it is at risk during thyroidectomy, carotid surgery, and mediastinal procedures; injury can lead to hoarseness, vocal cord paralysis, dysphagia, and aspiration. In the abdomen, vagal dysfunction contributes to conditions such as gastroparesis, functional dyspepsia, and altered gut motility. The clinical importance of **VNS** has increased because it provides an adjunctive option in patients who do not respond adequately to drugs or conventional rehabilitation. It is approved or cleared for medication-refractory epilepsy, treatment-resistant depression, obesity, migraine, cluster headache, and post-stroke motor rehabilitation.[2]

Even though it is so important clinically, the anatomy of the **vagus nerve** can be challenging. It spans multiple brainstem **nuclei**, follows a complex course in the neck, takes different paths on the right and left sides in the thorax, and then spreads widely through the abdomen. This article breaks down the gross and functional anatomy of the **vagus nerve**—from brainstem to abdomen—and focuses on **vagus nerve stimulation** and its clinical importance.

Methods

This narrative review brings together classic anatomical descriptions and **VNS**. We drew on up-to-date anatomical reviews, neuroanatomy resources, and surgically focused mapping studies of the **vagus nerve** and its branches

Relevant literature was identified from PubMed, PMC, and recent review articles using the search terms “vagus nerve stimulation,” “**VNS** mechanisms,” and “transcutaneous auricular **vagus nerve stimulation**.”

Results

Anatomical basis [9]

The **vagus nerve** exits the medulla oblongata through the jugular foramen and descends within the carotid sheath between the internal jugular vein and the carotid artery. It gives rise to auricular, pharyngeal, laryngeal, cardiac, pulmonary, and abdominal branches.[3]

1. Nuclear Origin and Functional Components [9]

The **vagus nerve** arises from the lateral part of the medulla oblongata. It emerges as 8–10 small rootlets from the post-olivary (posterolateral) sulcus, which lies between the olive and the inferior cerebellar peduncle, just below the glossopharyngeal nerve.

It is connected to four brainstem nuclei, each giving rise to a different functional component:

1. Nucleus ambiguus (branchial motor; special visceral efferent)

- Supplies muscles of the soft palate (except tensor veli palatini), the pharyngeal constrictors, and all intrinsic muscles of the larynx via the recurrent laryngeal nerve.
- Essential for swallowing, voice production, and protecting the airway.

2. Dorsal motor nucleus of **vagus** (**parasympathetic**; general **visceral** efferent)

- Situated in the floor of the fourth ventricle in the dorsal medulla.
- Sends preganglionic **parasympathetic** fibers to thoracic and abdominal organs as far as the splenic flexure.
- Controls heart rate, bronchial tone, gut motility, and glandular secretions.

3. Nucleus tractus solitarius (**visceral sensory**; general and special **visceral** afferent)

- Receives sensory input from thoracoabdominal organs, the carotid body and sinus (along with CN IX), and taste fibers from the epiglottis and root of the tongue.
- Integrates information related to cardiorespiratory function, digestion, and taste.

4. Spinal trigeminal nucleus (general somatic afferent)

- Receives somatic **sensory** input from the external acoustic meatus, part of the auricle, and the dura of the posterior cranial fossa.

Around 80% of vagal fibers are afferent, carrying **visceral sensory** information up to the brainstem and higher centers.

2. Intracranial Course and Exit from Skull [9]

- The rootlets of the **vagus nerve** join together to form the main nerve within the posterior cranial fossa.
- It then passes through the jugular foramen (posterior pars vascularis), along with the glossopharyngeal (CN IX) and accessory (CN XI) nerves and the internal jugular vein.
- Two sensory ganglia are present along its course:
- Superior (jugular) ganglion – small, mainly somatic sensory.
- Inferior (nodose) ganglion – larger, **visceral sensory**; contains cell bodies of afferents projecting to the nucleus tractus solitarius.

3. Cervical Relations [9]

In the neck, the **vagus nerve**:

- Gives off several important branches in the cervical region. Key cervical branches:
- Meningeal branch: Carries **sensory** fibers to the dura of the posterior cranial fossa.
- Auricular branch (nerve of Arnold): Supplies the external acoustic meatus and part of the auricle; stimulation can trigger cough (Arnold's reflex).
- Internal laryngeal nerve: **Sensory** to the laryngeal mucosa above the vocal cords.
- External laryngeal nerve: **Motor** to the cricothyroid muscle, which tenses the vocal cords.

4. Thoracic Branches [9]

The right and left **vagus nerves** take different paths through the thorax.

Right **vagus nerve**:

- Gives off the right recurrent laryngeal nerve, which loops under the right subclavian artery and then ascends in the tracheoesophageal groove to reach the larynx.
- Continues posterior to the root of the right lung, contributing to the pulmonary and esophageal plexuses.

Left **vagus nerve**:

- Gives off the left recurrent laryngeal nerve, which loops under the aortic arch (near the ligamentum arteriosum) and ascends in the tracheoesophageal groove.
- Passes posterior to the root of the left lung, contributing to the pulmonary and esophageal plexuses.
- Recurrent laryngeal nerves: **Motor** to all intrinsic laryngeal muscles except cricothyroid; **sensory** to the larynx below the vocal cords.

5. Abdominal Distribution [9]

At the esophageal hiatus of the diaphragm, the esophageal plexus condenses into two main trunks:

- Anterior vagal trunk (mainly from the left vagus):
- Lies on the anterior surface of the esophagus and stomach..
- Posterior vagal trunk (mainly from the right vagus):
- Lies on the posterior surface of the esophagus and stomach.

Functionally, the abdominal **vagus** controls gastric acid secretion, peristalsis, pancreatic and biliary secretion, and coordinates gut–brain signaling through its **visceral** afferent fibers.

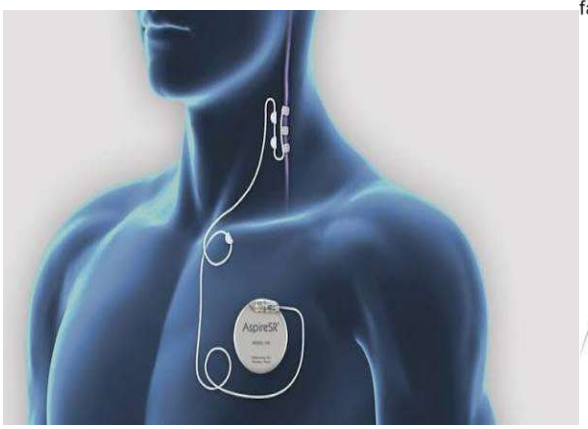

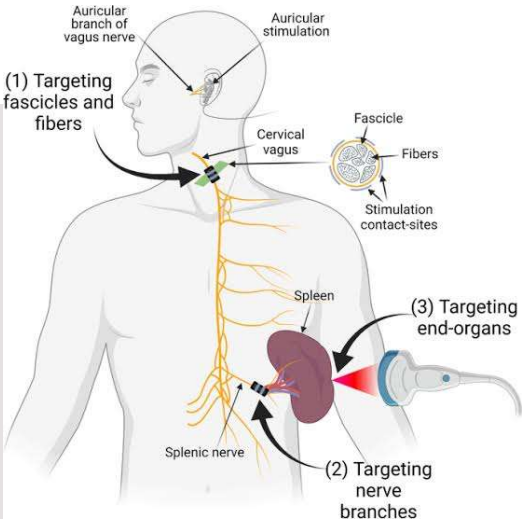

6. Vagus nerve stimulation

In invasive **VNS**, the electrode is usually placed around the left **vagus nerve** in the neck, because stimulation of the right **vagus nerve** may have a greater effect on cardiac conduction. The implanted generator is positioned subcutaneously in the upper chest and connected to the cervical electrode by a lead wire.[4]

The afferent vagal fibres project mainly to the nucleus tractus solitarius in the medulla. From there, signals reach the locus coeruleus, dorsal raphe nucleus, amygdala, hippocampus, hypothalamus, thalamus, and cerebral cortex. This widespread network explains the effects of **VNS** on seizures, mood, pain, inflammation, and autonomic regulation.[1],[7]

Mechanisms of action

VNS produces its effects through several interacting mechanisms:

- Anticonvulsant effect: **VNS** alters neuronal excitability and synchronisation, thereby reducing seizure frequency and severity.[1]
- **Neurotransmitter** modulation: It influences serotonin, norepinephrine, GABA, glutamate, and dopamine systems, which may contribute to its antidepressant and mood-stabilising effects.[7]
- Anti-inflammatory pathway: **VNS** activates the cholinergic anti-inflammatory pathway, suppressing pro-inflammatory cytokines such as tumour necrosis factor-alpha (TNF-α), interleukin-1 beta (IL-1β), and interleukin-6 (IL-6).[7]
- Neuroplasticity: **VNS** may enhance synaptic plasticity, supporting motor recovery after stroke and learning-based rehabilitation.[2],[7]
- Autonomic regulation: It modulates heart-rate variability, gastrointestinal motility, and metabolic homeostasis through afferent and efferent vagal pathways.[5]

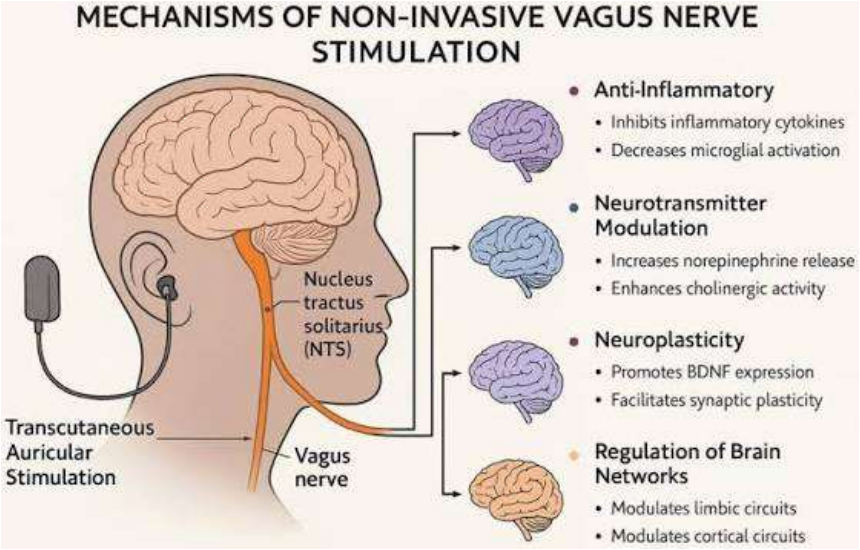

7. Functional Summary

The **vagus nerve** carries four major functional components:

1. General **visceral** efferent (GVE): **Parasympathetic** fibers to the heart, lungs, and gastrointestinal tract up to the splenic flexure.
2. Special **visceral** efferent (SVE): Branchial **motor** fibers to the pharynx and larynx.
3. General and special **visceral** afferent (GVA/SVA): **Sensory** fibers from thoracoabdominal viscera and taste fibers from the epiglottis and root of the tongue.
4. General somatic afferent (GSA): **Sensory** fibers from the external ear and the dura of the posterior cranial fossa.

Condition	Role of VNS
Drug-resistant epilepsy	Adjunctive therapy to reduce seizure frequency
Treatment-resistant depression	Adjunctive neuromodulation in patients unresponsive to antidepressants
Post-stroke motor deficit	Adjunct to rehabilitation for upper-limb motor recovery
Obesity	Modulation of appetite, satiety, and metabolic signalling
Migraine and cluster headache	Preventive or acute neuromodulatory therapy
Rheumatoid arthritis and inflammatory disease	Potential immunomodulatory therapy
Cardiovascular and cerebrovascular disease	Potential cardioprotection and neuroprotection

Safety and adverse effects

Invasive **VNS** is generally considered safe, but it is associated with procedure-related and stimulation-related adverse effects. Common stimulation-related effects include hoarseness, throat tingling, cough, dyspnoea, neck pain, and headache.[4]

Less common but important complications include infection, lead fracture, generator malfunction, vocal-cord dysfunction, and cardiac rhythm changes. Because of possible bradycardia or asystole during intraoperative testing, careful cardiac monitoring is recommended.[4]

Non-invasive taVNS generally has a more favourable safety profile, with mild local skin irritation, tingling, dizziness, or headache being the most frequently reported effects.[5]

Discussion

VNS represents a bridge between neuroanatomy, autonomic physiology, and clinical therapeutics. Its value lies not merely in direct electrical stimulation of a peripheral nerve, but in the ability of vagal afferents to influence widely distributed brain networks involved in seizure control, mood regulation, pain perception, inflammation, and **motor** recovery.[1],[7]

The strongest clinical evidence remains in drug-resistant epilepsy and treatment-resistant depression. In these conditions, **VNS** is usually considered after failure of conventional pharmacological and psychological treatments.[2],[3] Its gradual onset of benefit, particularly in depression, means that patients and clinicians should be counselled that improvement may continue over months rather than occurring immediately.[3]

The development of taVNS is especially important because it avoids surgical implantation and may expand access to **neuromodulation**. However, the evidence base for taVNS is still developing, and standardisation of stimulation parameters—such as intensity, frequency, pulse width, session duration, and treatment duration—is needed.[5]

From an anatomical perspective, **VNS** also highlights the clinical relevance of the **vagus nerve** as more than a **parasympathetic** nerve. Its afferent connections to the nucleus tractus solitarius and higher brain centres make it a major neuroimmune and neuroendocrine communication pathway.[5],[7] This has implications for future research in inflammatory diseases, metabolic disorders, cognitive dysfunction, and rehabilitation medicine.

Conclusion

Vagus nerve stimulation (**VNS**) has evolved from an anatomically grounded **neuromodulatory** concept into an established clinical therapy, with its strongest evidence in drug-resistant epilepsy and treatment-resistant depression. By engaging vagal afferent pathways that influence brainstem, autonomic, neuroimmune, and cortical networks, **VNS** can modulate neurotransmitter release, synaptic plasticity, inflammation, and autonomic balance.

Its clinical utility is no longer confined to neuropsychiatry: **VNS** is approved or increasingly investigated for headaches, stroke rehabilitation, obesity, inflammatory disorders, and other neurological and metabolic conditions. The emergence of non-invasive transcutaneous auricular **VNS** and closed-loop stimulation further expands its accessibility and potential for individualized treatment.

. The precise mechanisms underlying many therapeutic effects are incompletely defined, clinical responses vary substantially between patients, and further rigorous trials are needed to confirm efficacy across emerging indications. Nevertheless, important challenges remain. Future progress will depend on better targeting of vagal fiber populations, optimized stimulation parameters, closed-loop feedback systems, and personalized approaches guided by biomarkers and clinical response.

The **VNS** device has a lot of scope for further development. Research is being conducted to invent a more cost-friendly device so it can be available to middle-class people. There are some manual methods to stimulate the **vagus nerve** by deep diaphragmatic breathing, vocalization like chanting and humming, and cold exposure, etc. There is no clinical evidence of the effectiveness of the manual **VNS** method as compared to the **VNS** device.

References

1. A Review of Vagus Nerve Stimulation for Disease: Comprehensive Theory and Evidence for Mechanisms of Action. Comprehensive Physiology. 2026.

2. Vagus nerve stimulation (VNS): recent advances and future directions. Autonomic Neuroscience. 2024.

3. Vagus Nerve Stimulator. In: StatPearls. Treasure Island (FL): StatPearls Publishing; 2023.

4. A Comprehensive Review of Vagus Nerve Stimulation for Depression. Neuromodulation. 2022.

5. A Brief Review of the Evolution and Clinical Utility of Vagus Nerve Stimulation. Neuromodulation. 2022.

6. Vagus Nerve Stimulation. CNS Spectrums. 2014.

7. Mechanism and Applications of Vagus Nerve Stimulation. CNS Neuroscience & Therapeutics. 2025. Available from: https://pmc.ncbi.nlm.nih.gov/articles/PMC11854789/

8. vagus nerve stimulation, in mayoclinic, https://www.mayoclinic.org/tests-procedures/vagus-nerve-stimulation/about/pac-20384565

9. Chaurasia BD. BD Chaurasia's Human Anatomy. Vol. 3: Head, Neck and Brain. 8th ed. New Delhi: CBS Publishers & Distributors; 2020.