REDEFINING ESTHETICS: SOFT TISSUE ANALYSIS – A Review Article

Dr. Vaibhavi R. Kadam[1],Dr. Sheetal Yamyar[1], Dr. Akshay Kokate[2] ,Dr. Shubhada Bedse[3], Dr. Bhinika Wadher

PG Student, PG Guide and Associate professor, PG Student, Department of Orthodontics & Dentofacial Orthopaedics, CSMSS Dental College And Hospital.

Received:Oct 21, 2026 Accepted:Nov 18, 2026 Published:Nov 19, 2026

ABSTRACT:

Achieving and maintaining excellent facial appearance is one of the main objectives of orthodontic therapy. In order to ensure that the orthodontic correction will not negatively impact the normal facial trait, it is crucial that the orthodontist perform a comprehensive face assessment. To do this, a precise diagnostic and treatment planning are required. Thus, a review of some soft tissue analysis is covered in this article.

Keywords: Soft tissue analysis, orthodontic, diagnosis, facial examination & treatment planning.

.

INTRODUCTION

Facial esthetics is one of the main goals of orthodontic treatment and increased emphasis has been placed on it in recent years by both patients and orthodontists.[11] The famous Greek philosophers Plato and Aristotle introduced the term “aesthetics”, which means the study of beauty and philosophy of art.[1] Aesthetics not only includes physical and natural beauty but also the beauties of human emotion and experience.

The orthodontists then rightfully streamlined “aesthetics” to “esthetics” and limited its scope to only those criteria easily manageable by objective analysis.[7] Facial profiles and facial balance is a constant, continuous study and learning process for orthodontists. Tooth movement and proper positioning of the teeth to ensure favourable facial changes and to avoid unfavourable changes should be in the orthodontist’s “diagnostic” mind from the very first examination.[4]

Considerations of facial esthetics always have been an inseparable part of the principles and practice of orthodontics. The soft tissue profile has been studied extensively in orthodontics, primarily from lateral cephalometric radiographs, under the assumption that the form of soft tissue outline largely determines the esthetics of the face.

In problem-oriented treatment planning, we identify the problems that require improvement or correction and focus primarily on correcting those problems. We propose that the next fundamental component in treatment planning in the contemporary orthodontic analysis

should include identifying and quantifying the positive aspects of the patient's esthetic arrangement.

In this approach to problem-oriented treatment planning, we clearly want to fix what is wrong, but not at the expense of what is right about a patient's esthetic presentation.

Peck and Peck studied 88 private orthodontic patients, including retention patients, and found that the upper lip position on smiling was 1.5 mm higher in females than in males.

Vig and Brundo found that there is a gradual decrease in exposure of the maxillary central incisor with age. The mandibular anterior teeth, in turn, show a gradual increase with age. Maxillary incisor exposure decreases, on average, 3.4 mm from the second to the sixth decade of life, while mandibular incisor exposure increases an average of 2.4mm.

This position of the lip has also been defined as the smile line. Orthodontists have relatively good control over this line and can set treatment objectives to position the maxillary incisors in their most pleasing vertical position, both at rest and smiling.[14-26]

CEPHALOMETRIC SOFT TISSUE LANDMARKS[5,8]

One of the most important components of orthodontic diagnosis and treatment planning is the evaluation of the patient's facial soft tissue. Since the shape of the human face depends on both the structure of the hard tissue (bone) and the soft tissue that covers it, soft tissue should be analysed for the correct evaluation of an underlying skeletal discrepancy because of individual differences in soft tissue thickness.[5]

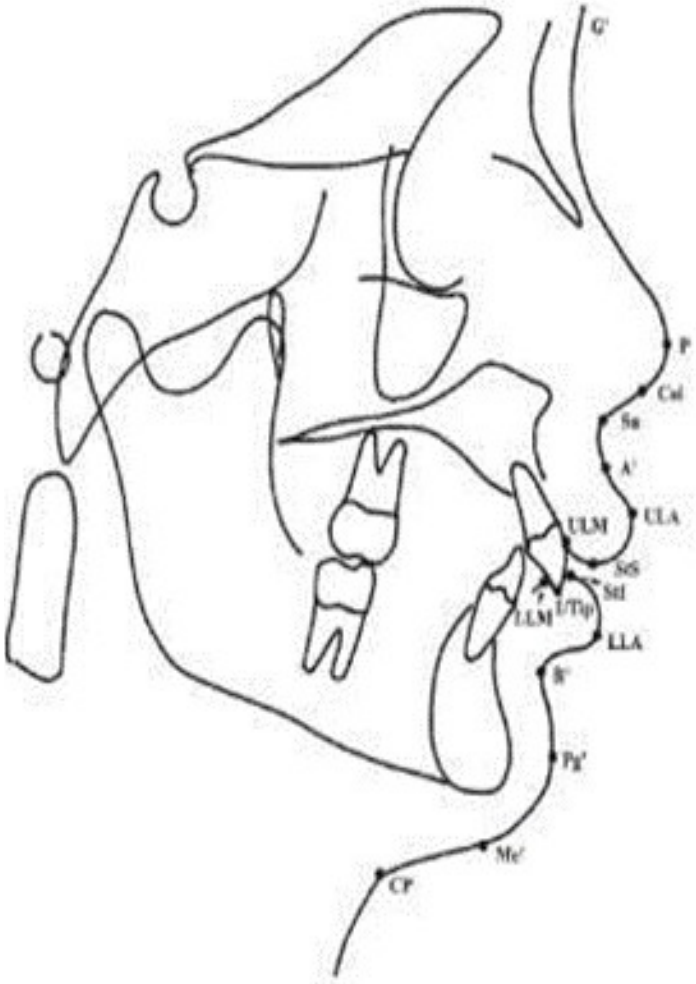

Soft Tissue Landmarks

G'	Soft Tissue Glabella
P	Pronasale
Col	Columella
Sn	Subnasale
A'	Soft Tissue A Point
ULA	Upper Lip Anterior Point
ULM	Upper Lip mucosa side opposite A'
Sts	Stomion Superiora
I/Tip	Tip of Upper Incisor
Sti	Stomion Inferious
LLA	Lower Lip Anterior Point
B'	Soft Tissue B Point
LLM	Lower Lip mucosa side opposite B'
Pg'	Soft Tissue Pogonion
Me'	Soft Tissue Menton
CP	Cervical Point

G-glabella	**most anterior point on the soft tissue forehead**
Li-labrale inferius	**most anterior point on the convexity of lower lip**
Ls-labrale superius	**most anterior point on the convexity of upper lip**
Ms-menton soft tissue	**most inferior point of the soft-tissue outline of the chin**
Ns-nasion soft tissue	**most concave point of the soft tissue on the frontal aspect of the bridge of the nose**
Pn-pronasale	**most anterior point of the nose**
SBN-Subnasale	**point at which the columella merges with the upper cutaneous lip**
Cm-Columella	**most anterior and inferior point of the nose**
Pog-pogonion soft tissue	**most anterior point on the convexity of the soft tissue chin**
Sls-superior labial sulcus	**most posterior point on the concavity between the upper lip and nose**
Stm-stomion	**midpoint of the labial fissure when the lips are closed naturally**
Sti-stomion inferior	**superior point of the lower lip**
Sts-stomion superior	**inferior point of the upper lip**

Various Soft Tissue Analysis:

1) **Holdaway Soft Tissue Analysis**[3]

Holdaway outlined 11 soft tissue parameters for soft tissue balance & the H-line or harmony line was formed by drawing tangent to the soft-tissue chin and the upper lip;

i) **Facial angle** formed by intersection of FH plane with line joining N to Pog. Average value 90^0 - 92^0. Used to measure the degree of protrusion (increase facial angle) or retrusion (decrease facial angle) of lower jaw.

ii) **Soft tissue Subnasale to H line** measured as the distance of perpendicular made from subnasale to H line. Average 3 to 7mm, ideal 5mm

iii) **Skeletal convexity point A** is measured from N – Pog line to point A. Average value 2 to -2

iv) **Upper sulcus depth** measured from Subspinale to H line average value 5mm

v) **Lower sulcus depth** is measured from deepest point in the curvature between lower lip and the chin and the H line. Average value 5mm

vi) **Lower lip to H line** the ideal position of the lower lip to H line is 0 - 0.5mm anterior, but individual variations from 1mm behind to 2mm in front of the H line are considered to be in a good range.

vii) **The H angle** Formed between H line & line joining N to Pog. Average value 7-15mm

viii) **Nose tip to H - line** average value 12mm max

ix) **Upper lip thickness** is measured horizontally from point 2mm below point A to outer border of upper lip, average value 15mm

x) **Upper lip strain** is measured from vermilion border of upper lip to the labial surface of maxillary central incisor. If upper lip thickness is greater than upper lip strain then it indicates strain in upper lip

xi) **Soft tissue chin thickness** is measured from hard tissue Pogonion to soft tissue Pogonion. Average value 10 to 12 mm

Convexity Point A to N - Pog (in mm)	H angle (Degree)	
-5	5	
-4	6	
-3	7	
-2	8	
-1	9	
0	10	
1	11	
2	12	
3	13	**Best Range**
4	14	
5	15	
6	16	
7	17	
8	18	
9	19	
10	20	

Values of skeletal convexity with relation to H angle

2) Merrifield Z angle[5]

Formed by FH plane (Frankfort Horizontal Plane) & Profile line by drawing a line tangent to the soft-tissue chin and to the most anterior point of either the lower or upper lip, whichever was most protruding, and extending it upward to Frankfort plane, this is a modification of the H line used by Holdaway. Normal range $70^0 – 80^0$ Ideal $75^0 – 78^0$.

3) E line[9,10]

Also called as esthetic line, described by Ricketts. It is formed by joining tip of nose and soft tissue pogonion.

4) S line[12,13]

Steiners S line is drawn from midpoint between Sub-Nasale (Sn) and Pronasale (Pn) to Soft Tissue Pogonion (Pog) and lip prominence with reference to this line is assessed. Its cephalometric norms are as follows:

- Upper lip to S Line (0 ± 2mm)
- Lower lip to S Line (0 ± 2mm)

5) COGS analysis (cephalometrics for orthognathic surgery)[2]

The analysis was developed by Charles J. Burstone in 1978. In this analysis, Burstone et al. used a plane called horizontal plane, which was constructed of Frankfurt Horizontal Plane.

Landmark Name	Landmark Symbol	Description	Normal
Facial forms analysis			
Facial convexity/Contour angle	G-Sn-Pog	Increased +ve value – Convex Profile Increased -ve value – Concave Profile	$12^0 \pm 4^0$
Maxillary Prognathism	G-Sn	+ve Prognathism -ve Retrognathism	6 ± 3 mm
Mandibular Prognathism	G-Pog	Increased -ve Mandible Retrognathism	0 ± 4 mm
Vertical Height Ratio	G-Sn / Sn-Me	Ratio of Middle 3rd to Lower 3rd Facial height	1 : 1
Lower Face Throat Angle	Sn-Gn-C	Helpful in correcting antero	$100^0 \pm 7^0$

		-posterior facial dysplasias	
Lower Vertical Height Depth Ratio	Sn-Gn / C-Gn	Determining the feasibility of reducing/increasing chin prominence (if ratio is >1 short neck)	1.2 : 1
Lip position and form			
Nasolabial Angle	Cm-Sn-Ls	Assessing the anteroposterior maxillary dysplasias	$102^0 \pm 8^0$
Upper Lip Protrusion	Ls to Sn-Pog	Abnormality treated by retracting/protracting incisors, surgically or orthodontically advancing or retracting the maxilla	3±1 mm
Lower Lip Protrusion	Li to Sn-Pog	Abnormality treated by retracting/protracting incisors, surgically or orthodontically advancing or chin prominence	2±1 mm
Mentolabial Sulcus Depth	Li-Pog’	Sulcus of 4mm provides a pleasing lower lip to chin contour	4±2 mm
Vertical Lip Chin Ratio	Sn -Stms / Stmi-Me	If ratio less than normal - vertical reduction genioplasty is recommended	1 : 2
Maxillary Incisor Exposure	tip of upper central incisor to Stms	Increased due to vertical maxillary excess or short upper lip Decreased due	2±2 mm

		to vertical maxillary deficiency or larger upper lip	
Interlabial Gap	Stms-Stmi	Vertical maxillary excess – larger gap & lip incompetency Vertical maxillary deficiency – no gap & lip redundancy	2±2 mm

DISCUSSION

Soft tissue analysis plays a vital role in modern orthodontic diagnosis and treatment planning, as facial esthetics largely depends on the soft tissue profile rather than only skeletal structures. Variations in soft tissue thickness can mask or exaggerate underlying skeletal discrepancies, making its evaluation essential.

Various analyses such as Holdaway, Merrifield's Z-angle, Ricketts' E-line, Steiner's S-line, and Burstone's COGS provide guidelines to assess lip position, facial convexity, and overall harmony. However, no single analysis is sufficient; a combination should be used for accurate assessment.

Additionally, soft tissues are dynamic and influenced by growth, aging, and treatment, so predicting these changes is important to avoid unfavorable esthetic outcomes. With advancements in computerized cephalometry, integrating radiographs, photographs, and models has improved diagnostic accuracy and treatment planning.

Overall, soft tissue evaluation is crucial for achieving balanced, esthetic, and stable orthodontic results

CONCLUSION

Today, more so than at any other time in our specialty, we have the ability to provide esthetic results to our patients. We have a good understanding of the changes that occur in the soft tissues with growth and the changes produced by our treatment. Comprehensive cephalometric and facial analyses allow us to identify the structural etiology of the malocclusion. Careful examination and documentation of soft tissue features will permit the reversal of negative traits and the maintenance of positive features in individuals, thereby enhancing clinical treatment.

As computer technology has become more sophisticated it has become possible to combine and integrate the benefits of cephalogram, patient photos and study models into one diagnostic package. Computerized cephalometry will continue to evolve rapidly, presenting both a challenge and an opportunity to the dental profession to improve visualization of the esthetic and functional impact of treatment plans.

REFERENCES

1. Abu Alhaija, ES & Al-Khateeb, SN 2011, 'Skeletal, dental and soft tissue changes in Class III patients treated with fixed appliances and lower premolar extractions', Australian Orthodontic Journal, vol. 27, no. 1, pp. 40.
2. Burstone, CJ, James, RB, Legan, H, Murphy, GA, & Norton, LA 1978, 'Cephalometrics for orthognathic surgery', Journal of Oral Surgery, vol. 36, no. 4, pp. 269–277.
3. Holdaway, RA 1983, 'A soft-tissue cephalometric analysis and its use in orthodontic treatment planning Part I', American Journal of Orthodontics, vol. 84, no. 1, pp. 1-28.
4. James, RD 1998, 'A comparative study of facial profiles in extraction and non-extraction treatment, American Journal of Orthodontics and Dentofacial Orthopedics, vol. 114, no. 3, pp. 265-276.
5. Moshkelgosha, V, Fathinejad, S, Pakizeh, Z, Shamsa, M & Golkari, A 2015, 'Photographic facial soft tissue analysis by means of linear and angular measurements in an adolescent persian population', The Open Dentistry Journal, vol. 9, no. 1, pp. 346.
6. Merrifield, LL 1966, 'The profile line as an aid in critically evaluating facial esthetics', American Journal of Orthodontics and Dentofacial Orthopedics, vol. 52, no. 11, pp. 804-822.
7. Peck, H & Peck, S 1970, 'A concept of facial esthetics', The Angle Orthodontist, vol. 40, no. 4, pp. 284-317.
8. Phillips, C, Greer, J, Vig, P & Matteson, S 1984, 'Photocephalometry: errors of projection and landmark location', American journal of orthodontics, vol. 86, no. 3, pp. 233-243.
9. Ricketts, RM 1961, 'Cephalometric analysis and synthesis', The Angle Orthodontist, vol. 31, no. 3, pp. 141-156.
10. Ricketts, RM 1968, 'Esthetics, environment, and the law of lip relation', Am. J. Orthod., vol. 54, no. 4, pp. 272- 289.
11. Spyropoulos, MN & Halazonetis, DJ 2001, 'Significance of the soft tissue profile on facial esthetics', American Journal of Orthodontics and Dentofacial Orthopedics, vol. 119, no. 5, pp. 464-471.
12. Steiner, CC 1959, 'Cephalometrics in clinical practice', The Angle Orthodontist, vol. 29, no. 1, pp. 8-29.
13. Steiner, CC 1960, 'The use of cephalometrics as an aid to planning and assessing orthodontic treatment: report of a case', American Journal of Orthodontics and Dentofacial Orthopedics,

vol. 46, no. 10, pp. 721-735.

14. Terry DA, Pirtle PL. Learning to smile: The neuroanatomic basis for smile training. J Esthet Restor Dent 2001; 13:20-27. Peck H, Peck S. A concept of facial esthetics. Angle Orthod 1970; 40:284–317.
15. Tjan AHL, Miller GD, Josephine GP. Some esthetic factors in a smile. The J Prosthet Dent 1984 Jan; 51(1):25–29.
16. Moskowitz ME, Nayyar R. Smile analysis and principles of visualization. Compend Contin Educ Dent 1995; 16:1168-86.
17. Bisson M, Grobbelaar A. Esthetic Properties of Lips: A Comparison of Models and Nonmodels. Angle Orthod 2004; 74:162-166.
18. Ackerman MB, Brensinger C, Landis R. An evaluation of Dynamic Lip-tooth Characteristics during speech and smile in adolescents. Angle Orthod 2004; 74:43-50.
19. Zachrisson BU. Esthetic Factors Involved in Anterior Tooth Display and the Smile: Vertical Dimension. J Clin Orthod 1998;35(7):432-45.
20. Moskowitz ME, Nayyar R. Smile analysis and principles of visualization. Compend Contin Educ Dent 1995; 16:1168-86.
21. Burrstone CJ. The integumental profile. Am J Orthod 1958; 4:01-25
22. Morley J, Eubank J. Macroesthetic elements of smile design. J Am Dent Assoc 2001 Jan; 132:39–45.
23. Ackerman MB, Ackerman JL. Smile analysis and design in the digital era. J Clin Orthod 2002; 36(4):221-36.
24. Monaco A, Streni O, Marci MC, Marzo G, Gatto R, Giannoni M. Gummy smile: clinical parameters useful for diagnosis and therapeutical approach. J Clin Pediatr Dent 2004; 29(1):119-26.
25. Mashid M, Khoshraghti A, Varshosaz M, Vallerei N. Evaluation of golden percentage in individuals with and esthetic smile. J Esthet Restor Dent 2004; 16:185-93.
26. Moore T, Southard KA, Casko JS, Qian F and Southard TE. Buccal corridors and smile esthetics. Am J Orthod Dentofacial Orthop 2005; 127:208-13.